



# SUBXIPHOID ROBOTIC APPROACH TO RESECTED THYMOMA: TIP, TRICKS AND PITALL

Nguyen Viet Dang Quang,  
Nguyen Hoang Binh, Chau Phu Thi, Dang Dinh Minh Thanh, Truong Cao Nguyen, Vu Huu Vinh

Thoracic Department

Cho Ray Hospital – VietNam



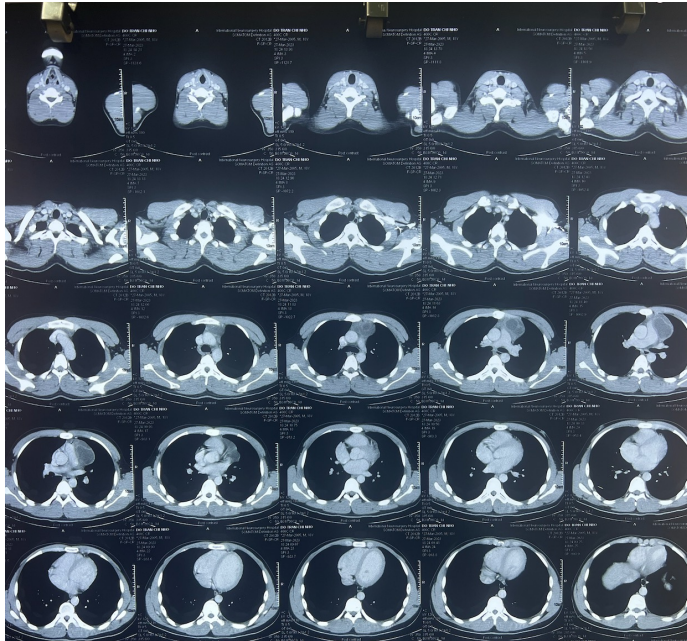
# BACKGROUND

- Biggest hospital in South of VietNam
- 2500 beds
- Mutil – specialists
- 5 centers
- Star robotic thoracic surgery since 7/2018





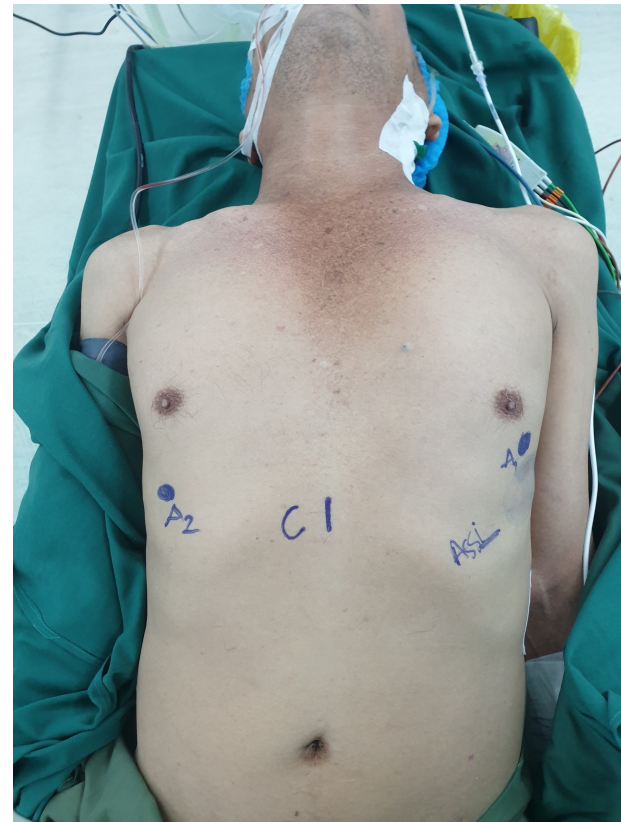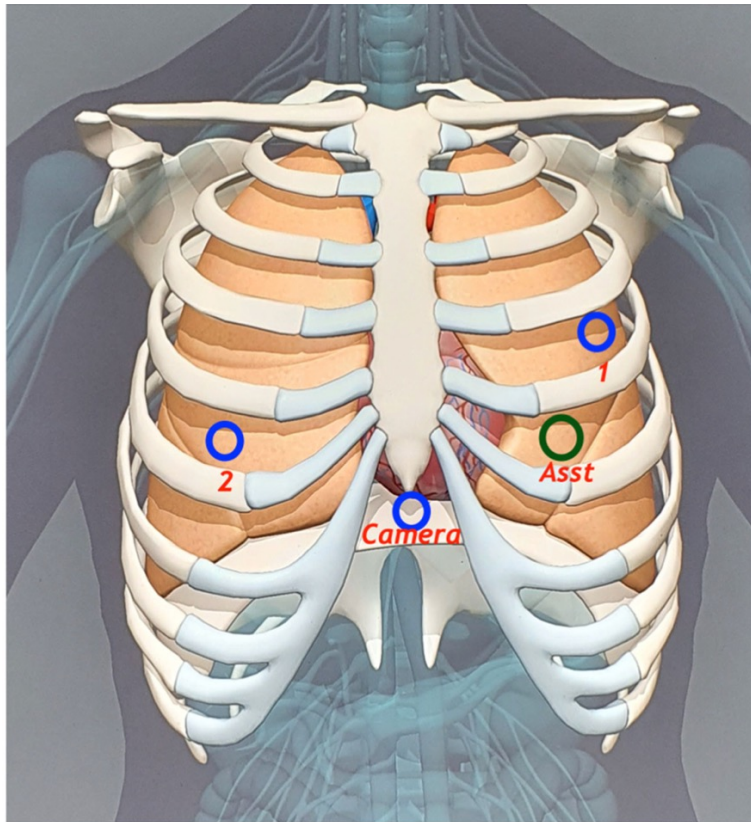
# CASE PRESENT



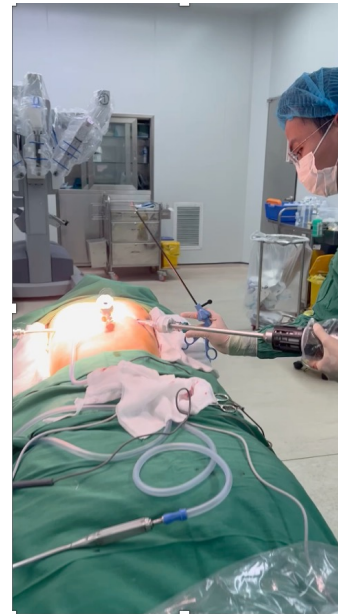
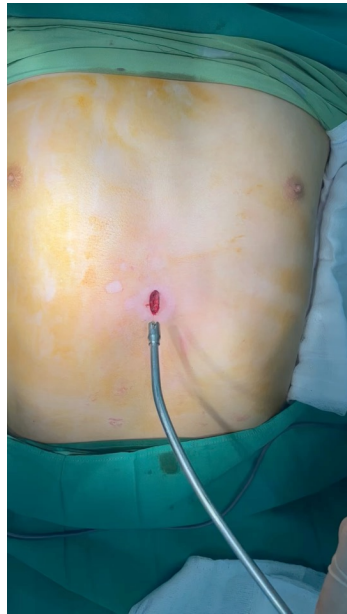- Male, 18 y-o
- Chest pain
- Thymoma on CT scan
- Pathology: teratoma. 6x7 cm



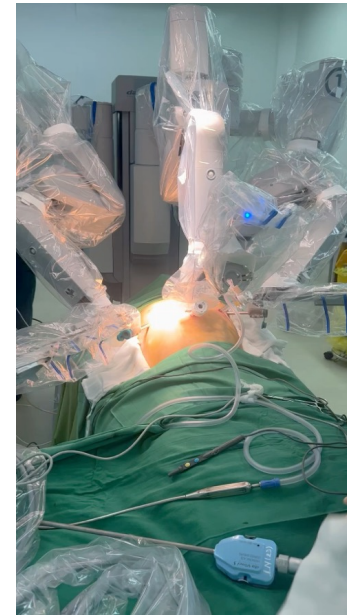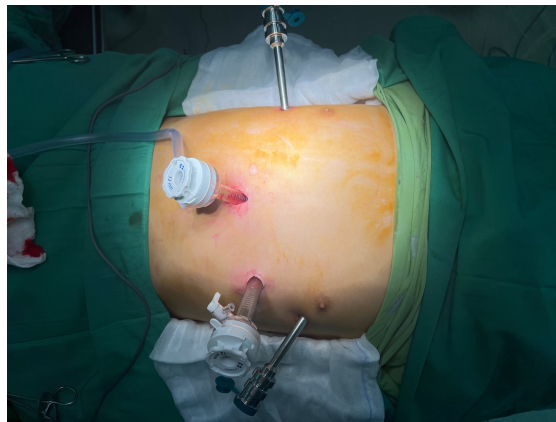# POSITION

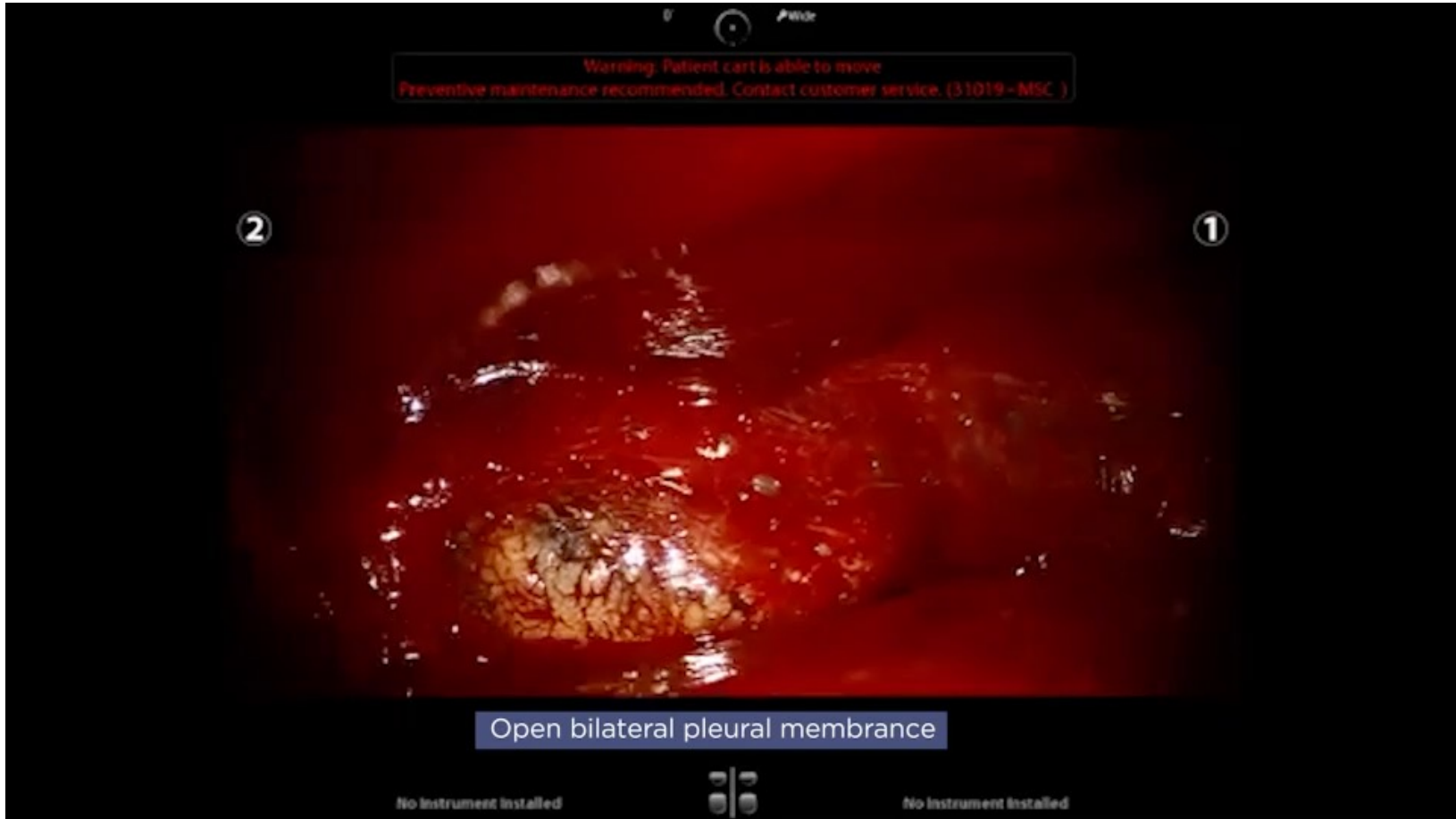


# PROCEDURE



# PROCEDURE



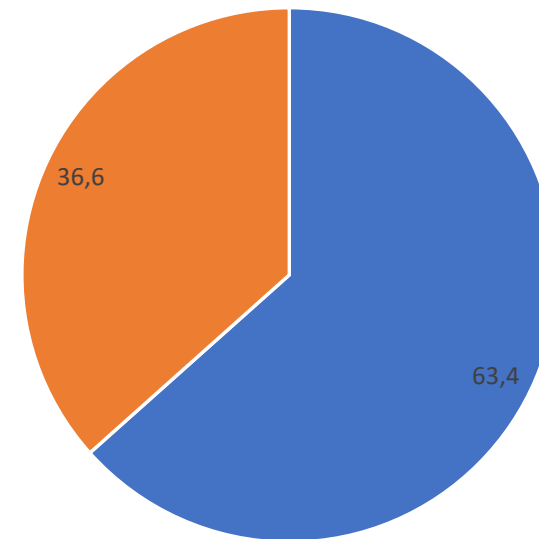


# Results

- From 1/2020 to 6/2023
- Total 52 patients who had thymoma

Mean age:  $50,5 \pm 10,6$  y-o  
Min: 31 y-o  
Max: 72 y-o

Gender



■ Male ■ Femal





# Results

Characteristics	Number	%
Myasthenia Gravis	10	19,2
Tumor size	4,2 ± 1,3 (min: 3cm ; max: 8cm)	
Masaoka		
Stage 1	13	25,0
Stage 2	38	73,1
Stage 3	1	1,9
Pathology		
Teratoma	8	15,5
Type A	11	21,1
Type AB – B1	20	38,4
Type B2 – B3	11	21,1
Carcinoma	2	3,9





# Results

## OPERATIVE CHARACTERISTICS

Operative time	102,0 ± 21,8 min
Time of removal chest tube	1,4 ± 0,6 days
Time of discharge	3,0 ± 1,3 days

01 case bleeding intraoperation → control without covert to open  
03 case : failure respiratory in post-op → mechanical ventilon  
01 case die due to pneumonia





# Take home message

- Robotic subxiphoid thymectomy in grande tumor → best view.
- Control innominate vein first, divided thymic vein.
- Resected from benign tissue to tumor side.
- Total thymectomy for thymoma





THANK YOU FOR YOUR ATTENTION

